

2026



ASMIRT

Guidelines

CT Intermediate Level Course Syllabus Study and Examination Guide

Your profession. Your future.



There are a number of protected titles for medical radiation practice. They include:

Medical Radiation Practitioner (MRP)

Diagnostic Radiographer (DR)

Medical Imaging Technologist (MIT)

Radiographer

Nuclear Medicine Scientist (NMS)

Nuclear Medicine Technologist (NMT)

Radiation Therapist (RT).

For the purposes of our documentation we use the broad descriptor Medical Radiation Practitioner (MRP) recognising that it covers a range of areas of practice.



info@asmirt.org
www.asmirt.org
PO Box 16234,
Collins Street West,
VIC 8007, Australia
+61 3 9419 3336

Contents

TOPICS	PAGE NUMBER
Overview	4
Justification	4
Examination preparation	5
Learning Objectives	5
Section A: Anatomy, physiology and CT pathology <ul style="list-style-type: none"> • Head • Neck/face 	6
Chest Abdomen Spine Physiology	7
Head Neck/face Chest Abdomen	8
Spine	9
Section B: Contrast agents, radiation protection and dosimetry <ul style="list-style-type: none"> • Contrast Agents • Radiation protection and dosimetry 	9
Section C: Physical principles, hardware and artefacts <ul style="list-style-type: none"> • Terminology • Image quality and quality assurance • Scanner Hardware 	10
Artefact 3D reformatting techniques Special techniques	11
Section D: CT technique	11
Routine image techniques CT angiography Special techniques	12
Reading material <ul style="list-style-type: none"> • CT texts • Anatomy texts • Websites 	13
Sample examination questions	15
The CT Intermediate Level Certification Examination Structure – An Overview	18
CT Intermediate Level Certification Examination Summary	22

CT Intermediate Level Course Syllabus Study and Examination Guide

Overview

The following key capabilities and enabling components cover the knowledge, skills and attributes needed by all diagnostic radiographers, nuclear medicine technologists and radiation therapists who use CT MRPBA Professional capabilities for medical radiation practice (2020) Domain 1A:

Key capabilities – What registered medical radiation practitioners must be able to do	Enabling components – Evidence of this capability for general registration as a medical radiation practitioner
Perform computed tomography (CT) imaging.	<ol style="list-style-type: none">Operate CT systems safely and effectively.Apply appropriate imaging parameters for the patient/client presentation.Adjust relative radiation dose levels based on the range of patient/client presentations.Collaborate in the design and evaluation of CT protocols.Perform and evaluate contrast and non-contrast CT examinations of the body and, when appropriate, modify them to consider patient/client presentation and clinical indications.Process data image sets, including multi-planar reformats and volume imaging.


Justification

ASMIRT is providing this certification as recognition that a medical radiation practitioner (MRP) is performing with professional skill in Computed Tomography (CT) imaging. This certification provides practitioners and employers with direction for study and educational programs, a benchmark of industry-standard skill, and formal recognition of the ability of the MRP.

CT Certification of medical radiation practitioners by ASMIRT implies MRPs have the knowledge to:

- Operate proficiently in an CT clinical environment and during complex procedures
- Assess patient suitability for and oversee safe administration of contrast media
- Evaluate appropriate CT protocols in co-ordination with radiologists and other appropriate clinical medical specialists.
- Individualise scanning technique to suit patient procedure
- Evaluate normal anatomy, and unexpected or urgent medical findings
- Understand ongoing quality assurance and safety implications





Introduction

The Intermediate level CT certificate is aimed at radiographers who have a minimum of 5 years full time equivalent experience in a broad range of CT examinations. In order to pass the theoretical component, candidates are expected to undertake revision of textbooks and other relevant literature prior to sitting the exam.

Intermediate CT certification encompasses theoretical and clinical components. In order for a candidate to apply for a 'CT Intermediate Level Certificate', the candidate must meet all of the following requirements:


1. Achieve a pass grade of 75% with no element below 65% for the CT Intermediate Level Certification examination (Part A)
2. Performed the required clinical component as outlined below (Part B)

Part A - Examination

The formal examination will involve a paper not exceeding 150 multiple-choice questions covering a range of topics (refer to the following study guide for details). The examination is divided into 4 sections. The table below indicates the number of questions related to each topic:

Part A:	Anatomy, physiology, and CT pathology	30 Questions
Part B:	Contrast agents, radiation protection and dosimetry	45 Questions
Part C:	Physical principles, hardware and artefacts	30 Questions
Part D:	CT techniques	45 Questions





Examination Preparation

CT Experience - this exam is not designed for candidates who have spent less than 5 years in a CT room. You are not precluded from sitting the examination, but past results have shown that it is extremely difficult to pass without significant hands on CT experience.

Study period - A pass in this examination is dependent on a well-designed and lengthy study program. Successful candidates have recommended a minimum of 6 months concentrated study.

Mentors- successful candidates have involved their work colleagues, previous successful candidates and a mentor. It is also recommended to use study material that contains multiple choice questions or review questions. There is no requirement to answer the section in any particular order, e.g. some candidates suggested answering the section that you are most familiar with first.

LEARNING OBJECTIVES

Section A: Anatomy, physiology and CT pathology

Applicants will be expected to be able to identify the following structures on standard CT images (including coronal, sagittal 3D and CT angiography images where applicable) and/or line drawings. Applications will also be expected to demonstrate knowledge of the spatial relationships of these structures.

Head

- Skeletal structures: sella turcica, foramen magnum, air sinuses (frontal, ethmoid, sphenoid), mastoid air cells, IAM, EAM, jugular foramen, carotid canal
- Arteries: vertebrals, basilar, internal carotids, posterior inferior cerebral artery, anterior and poster communicating arteries, and middle, anterior and posterior cerebrals
- Venous system: cavernous sinus, superior sagittal sinus, straight sinus, transverse sinus, internal jugular veins, confluence of sinuses
- Intra- cerebral ventricular system: lateral 3rd and 4th ventricles, choroid plexus, ambient (quadrigeminal) and basal (interpeduncular) cisterns
- Meninges: falx, tentorium cerebelli
- Cerebrum and cerebellum: pons, lobes (frontal, temporal, parietal, occipital) fissures (sylvian fissure, longitudinal fissure, central sulcus), corpus callosum, pituitary and pineal glands, thalamus, head of caudate nucleus, internal capsule, lentiform nucleus.

Neck/face

- Skeletal structures: maxillary sinuses, hyoid bone, styloid process
- Arteries: common carotid, internal carotid, external carotid, vertebral, subclavian, brachiocephalic
- Veins: internal and external jugular, subclavian, brachiocephalic





- Airway structures: cricoid cartilage, thyroid cartilage, epiglottis, pharynx, oesophagus, piriform fossa,
- Glands: thyroid, submandibular, parotid
- Muscles: Platysma, sternocleidomastoid, trapezius

Chest

- Skeletal structures: ribs, sternum
- Arteries: aorta, brachiocephalic, subclavian, pulmonary trunk
- Veins: IVC, SVC, subclavian, brachiocephalic, pulmonary, azygos
- Heart: atria, ventricles, pericardium, valves, arteries: left main, left anterior descending, right coronary, circumflex
- Airways: trachea, bronchi, carina
- Lungs: lobes, fissures, pleura

Abdomen

- Skeletal structures: pelvis, scrum, coccyx
- Arteries: abdominal aorta, celiac, SMA, renal, iliac, femoral
- Veins: IVC, renal SMV, portal, iliac, femoral, hepatic
- Organs: liver (gall bladder, common bile duct, other bile ducts), kidneys, adrenals, pancreas, spleen, bladder, ureters, prostate, seminal vesicles, uterus, ovaries
- GI tract: oesophagus, stomach, duodenum, colon, ovaries, seminal vesicles
- Muscles: psoas, quadratus lumborum, iliacus, transversus abdominus, rectus femoris

Spine

- Vertebral bodies, foramen, processes, articular surfaces, intervertebral discs, nerves

Physiology

- CSF production, circulation and absorption
- Cardiovascular circulation
- Portal venous blood supply





PATHOLOGY

Head

- Haemorrhage: subdural, extra-dural, sub-arachnoid, intra-cerebral
- Hydrocephalus
- Infarct (stroke)
- Space-occupying lesion

Neck/face

- Sinusitis
- Goitre
- Lymphadenopathy

Chest

- Pneumothorax
- Emphysema
- Infective disease
- Lymphadenopathy
- Bronchiectasis
- Pulmonary embolus

Abdomen

- Laceration of solid organs
- Hemangioma
- Renal/liver cyst
- Renal calculus
- Appendicitis
- Psoas abscess
- Pancreatitis
- Lipoma
- Ovarian cysts





Spine

- Trauma
- Disc herniation

Section B: Contrast agents, radiation protection and dosimetry

This section details the application of intravenous paramagnetic contrast media (CM) in CT. Applicants will be able to identify patients at risk and patients with contraindications to CM, describe emergency procedures for patient care after allergic-type reaction or extravasation of IV CM, outline pharmacological influences on IV CM use and scanning protocols and explain RANZCR safe-use guidelines including terminology and assess patient suitability for use of CM.

Contrast agents

- Pharmacology: Ionic vs non-ionic contrast, monomer versus dimer, viscosity, strength,
- osmolality, chemical structure
- Contraindications for oral and intravenous contrast agents
- Possible side effects
- Immediate treatment for contrast reactions
- Contrast-induced renal nephropathy: patients at risk, precautions
- Allergic-type reactions: patients at risk, precautions
- Use in pregnancy in lactation
- Administration routes
- Indications for use
- RANZCR guidelines on contrast administration

Radiation protection and dosimetry

- CT dose parameters: CTDI, DLP, effective dose
- Australian DRLs for routine CT of the head, neck, chest and abdomen
- Approximate effective doses for routine CT of the head, chest and abdomen
- Technical factors that influence patient dose
- The use of CT during pregnancy
- Special needs for paediatric patients
- Dose minimisation techniques





Section C: Physical principles, hardware and artefacts

On successful completion of this section the candidate will have a general understanding of the terminology used in CT, identify the key features to producing quality images including quality assurance, describe the hardware and technology and any artefacts produced in the images, along with 3D reformatting techniques and any other special techniques utilised in the CT scanner for image acquisition.

Terminology

- Pitch
- Hounsfield unit
- Pixel
- Algorithm/kernel
- Interpolation
- Window width and window level
- Image filter
- Display field of view
- Scan field of view

Image quality and quality assurance

- Noise
- High contrast resolution
- MTF
- Low contrast resolution
- Linearity
- Uniformity
- Cupping

Scanner hardware and technology

- Detector configurations
- Beam filtration
- Scanner configurations
- MSCT vs single slice
- Helical vs axial





Artefact

- Beam hardening
- Partial volume artefact
- Motion artefacts
- Calibration error
- Metal artefacts
- Zebra artefacts
- Windmill artefacts

3D reformatting techniques

- Surface shaded display
- Volume rendered display
- Maximum intensity projection
- Multiplanar reformation

Special techniques

- Cardiac CT: prospective vs retrospective gating, step-and-shoot mode vs helical mode
- CT brain perfusion: acquisition modes: shuttle/helical/wide volume, reporting parameters: mean transit time (MTT), time to peak (TTP), cerebral blood volume (CBV), cerebral blood flow (CBF), penumbra vs ischaemia
- Dual energy: acquisition modes (dual detector layer, kVp switching, dual tube, two acquisitions)

Section D: CT technique

Applicants will be able to demonstrate the principles of CT image acquisition for routine images, understand the effects of reconstruction parameters and their effects on anatomy and pathology and dose to patient and explain correction methods.

- Effect of acquisition and reconstruction parameters on image noise and high contrast resolution
- Effect of scan acquisition parameters on patient dose
- Helical vs non helical: indications for use, advantages and disadvantages of use
- Technique modification for paediatrics, trauma, patient size





- Contrast timing: available timing techniques, approximate scan delays for arterial, portalvenous, nephrogram and pancreatic phases

Routine image techniques for the following examinations:

- Head (routine)
- Inner ear
- Sinuses
- Face (trauma, infection, tumour)
- Neck
- Thorax (routine, HRCT, pulmonary)
- Abdomen: routine, multiphase liver, multiphase pancreas, multiphase kidney, renal colic
- Spine (including trauma)
- Extremities (including trauma)

CT angiography for the following:

- Brain
- Neck
- Chest (including CT pulmonary angiography)
- Abdomen and pelvis
- Lower limb

Special techniques (demonstrate theoretical understanding):

- Cardiac CT angiography: patient preparation, indications, systolic vs diastolic acquisition, helical vs step-and-shoot mode
- Cardiac calcium score: indications, acquisition
- Brain perfusion: indications
- CT colonography
- Dual energy





Reading Material

The recommended readings are considered by ASMIRT to provide the applicant with a sound understanding necessary to complete the theoretical component and assist with additional knowledge for the clinical aspects of Intermediate CT Certification. These texts are recommended only; applicants may choose to use other sources of information.

CT texts

- Kalendar, W.A. (2011). *Computed Tomography: Fundamentals, System Technology, Image Quality, Applications* (Third ed.). Munich: Publicis.
- DeMaio, D. N. (2011). *Mosby's exam review for computed tomography* (2nd ed.). St. Louis, Mo: Mosby Elsevier.
- Romans, L. E. (2010). *Computed tomography for technologists: Exam Review*. Baltimore, Md: Wolters Kluwer Health/Lippincott Williams & Wilkins.
- Romans, L. E. (2016). *Computed tomography for technologists: A comprehensive text*. Baltimore, Md: Wolters Kluwer Health/Lippincott Williams & Wilkins.
- Schoenhagen, P., Schultz, C. J., & Halliburton, S. S. (2014). *Cardiac CT made easy: An introduction to cardiovascular multidetector computed tomography* (Second ed.). Boca Raton: CRC Press/Taylor & Francis.
- Seeram, E. (2016). *Computed tomography: Physical principles, clinical applications, and quality control* (Fourth ed.). St. Louis, Missouri: Elsevier.

Anatomy texts

- Anderson, M. W., Fox, M. G., & El-Khoury, G. Y. (2017;2016;). *Sectional anatomy by MRI and CT* (Fourth ed.). Philadelphia, PA: Elsevier.
- Ellis, H., Logan, B. M., & Dixon, A. K. (2015). *Human sectional anatomy: Atlas of body sections, CT and MRI images* (4th ed.). Hoboken: CRC Press.
- Lazo, D. L. (2015). *Fundamentals of sectional anatomy: An imaging approach* (Second ed.). Stamford: Delmar.


Websites

- ARPANSA national diagnostic reference levels for multi detector computed tomography. Available from: <https://www.arpana.gov.au/research-and-expertise/surveys/national-diagnostic-reference-level-service/current-australian-drls-update/mdct>
- RANZCR guidelines for iodinated contrast. Available from: <http://www.ranzcr.edu.au/resources/professional-documents/guidelines>
- Radiopaedia. Available from www.radiopaedia.org Journal articles (free full text online)
- Halliburton, S., Arbab-Zadeh, A., Dey, D., et al. (2012). State-of-the-art in CT hardware and scan modes for cardiovascular CT. *Journal of Cardiovascular Computed Tomography*, 6(3), 154-163. doi:10.1016/j.jcct.2012.04.005



- McCollough, C. H., Leng, S., Yu, L., & Fletcher, J. G. (2015). Dual- and multi-energy CT: Principles, technical approaches, and clinical applications. *Radiology*, 276(3), 637-653. doi:10.1148/radiol.2015142631

Please refer to the Policies & Procedures Manual for up-to-date information on CT Intermediate Level Certification (Part A). This document can be found at: <https://www.asmirt.org/certification>





Sample Examination Questions:

1. The lateral ventricles of the brain are connected to the third ventricle by which of the following structures?

- (a) Ambient cistern
- (b) Cerebral aqueduct/Aqueduct of Sylvius
- (c) Interventricular foramen/Foramen of Monro
- (d) Foramen of Lushka

Answer: (c)

2. Which of the following statements about the portal venous system is false?

- (a) It drains blood from the bowel, spleen, pancreas and gallbladder
- (b) The portal vein is formed by the joining of the SMV and the splenic vein
- (c) The portal venous system transports blood directly to the IVC
- (d) Portal hypertension can result in the formation of oesophageal varices

Answer: (c)

3. A differential diagnosis of a haemangioma of the liver can be made from a multiphase scan of the liver if:

- (a) The lesion appears denser during the delayed phase than during the arterial or portal venous phase
- (b) The density of the lesion does not change with different phases of contrast enhancement
- (c) The lesion is less than 3cm in size
- (d) The lesion shows no enhancement in the arterial phase

Answer: (a)

4. Which of the following interactions between x-ray photons and matter results in the largest amount of patient dose?

- (a) Characteristic
- (b) Compton scatter
- (c) Bremsstrahlung
- (d) Photoelectric effect

Answer: (d)





5. Examples of mild adverse reactions to iodinated intravenous contrast media may include:

- (a) Nausea
- (b) Dyspnea
- (c) Warm, flushed sensation
- (d) 1 only

Answer: (c)

6. Increasing the scan field of view:

- (a) Increases the number of detector cells collecting data
- (b) Increases the range of HU displayed on the image
- (c) Decreases the pixel size
- (d) Decreases the display field of view

Answer: (a)

7. A CT slice is taken with the following factors: mA = 300, scan time = 1 second, matrix = 512, kVp = 120, slice thickness = 5mm. The resulting image is suspected of containing a considerable amount of volume averaging. Which of the following factors is primarily responsible?

- (a) mA
- (b) Scan time
- (c) Matrix
- (d) Slice thickness

Answer: (d)

8. A grid formed from columns and rows of pixels is called a?

- (a) Back projection
- (b) Convolution filter
- (c) Matrix
- (d) Histogram

Answer: (c)





9. The technique used in obtaining high resolution CT (HRCT) includes:

- (a) Thin collimation
- (b) Utilising a high spatial frequency algorithm or filter
- (c) Increased technical factors (kVp and mAs)
- (d) A & B only

Answer: (d)

10. The non-equilibrium phase of the liver usually occurs how long after the commencement of the injection?

- (a) 55-120 seconds
- (b) 2 minutes
- (c) 3-4 minutes
- (d) 3-4 hours

Answer: (a)

11. The adrenals should be included on a routine oncology chest scan because:

- (a) Lung may be seen below the adrenal glands
- (b) Lung is never seen below the adrenal glands
- (c) Adrenal glands enlarge with infection
- (d) Lung tumours can metastasize to the adrenals

Answer: (d)




The CT Intermediate Level Certification Examination Structure – An Overview

The examination involves a series of 150 directed questions which will be accessed from an online examination platform and displayed on a local computer system.

It will be conducted over a duration of 3 hours (180 minutes).

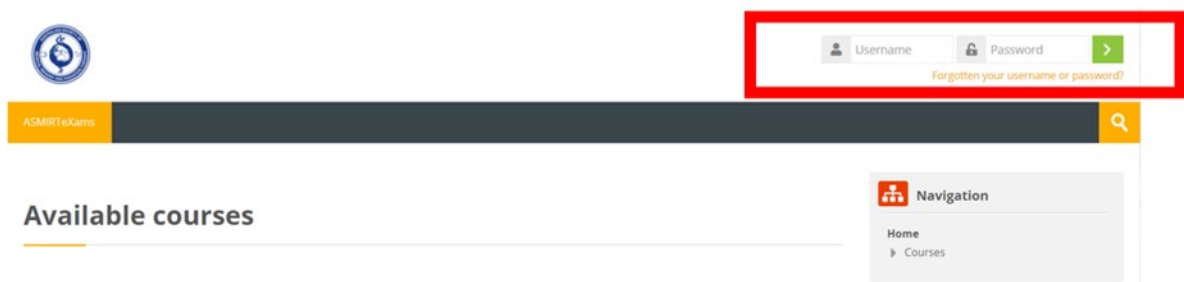1. The examination will be performed on a specific local I.T. / computer screen system.
2. Each examination question in each section will follow the same consistent approach for evaluating the correct answer using a multiple-choice answering system.
3. The candidate will access the on-line examination using a unique username and password (provided by ASMIRT). Once the candidate has entered the portal, the CT examination will be available on the dashboard for selection.
4. Once the candidate has selected the CT examination and are ready to commence the examination, they are permitted to do so.
 - The candidate has three (3) hours to complete the examination. A timer commences count down on the screen to show elapsed time.
 - After three (3) hours has elapsed, the candidate will no longer have access to the examination.



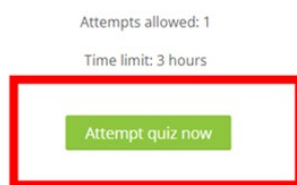


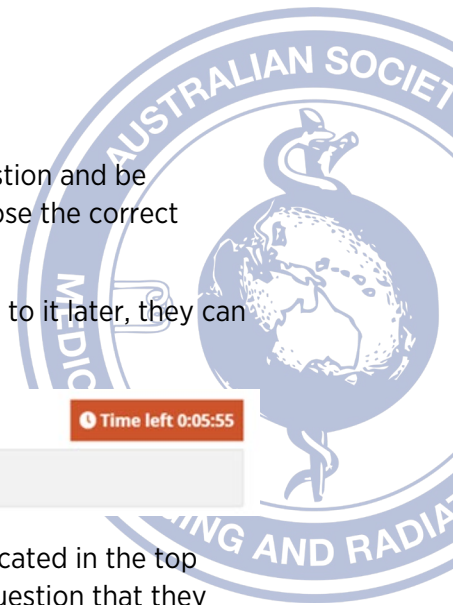
Pre – CT Intermediate Level Examination Platform Access (For Both Supervisor and Candidate)

1. Once the candidate has registered for the examination, the candidate will be required to nominate a supervisor to supervise this examination. The candidate will need to negotiate with the supervisor an appropriate date and time to undertake this examination. A supervisor declaration form will need to be completed and submitted to ASMIRT for approval.
2. Once the supervisor has been approved, they will be given access (via a unique username and password) to the examination portal to undertake a “Test” CT Examination.
 - URL link
 - Username: xxx
 - Password: xxx
3. This will ensure that the supervisor will be able to test the local computer that will be used for the examination to check any workplace “firewall” issues, suitability of the room/location including noise and light, functionality of the examination platform, and the examination process.
4. Concurrently, the candidate will be provided with their unique username and password, to enable the candidate to undertake a “practice” examination of anywhere between 2 to 4 questions to ensure there is an understanding of the functionality of the system.
5. ASMIRT recommends that the above checks by the supervisor and the examination preview by the candidate should be undertaken a week before the actual examination.
6. The candidate will be required to click on top right-hand side of the page and insert their unique username and password, then click on the green arrow to log in.



7. The candidate will then be presented with the examination. When the candidate is ready to begin, click on green button **ATTEMPT QUIZ NOW**.





- Upon viewing, the candidate will be presented with a directed question and be presented with several alternative answers and be required to choose the correct answer under a multiple-choice format.
- If the candidate is unsure about a question and would like to return to it later, they can “flag” the question by click on the flag.

Time left 0:05:55

Question 2 Answer saved Marked out of 1 **Flag question**

- This will also appear on the candidate’s Quiz Navigation section (located in the top right-hand corner of each question) as a red flag to highlight the question that they would like to return to.

Quiz navigation

1 2 3 4 5

Finish attempt ...

- The candidate should also note that once the question has been completed, that question will be highlighted in “grey” on the “Quiz Navigation” section on the right-hand side of the examination (See image above). The Quiz Navigation will indicate how many questions have been completed and the sections the questions are located in.
- Unanswered questions will be shown as blank. Those that are flagged and unanswered have a red flag and are blank.
- Please take note of the timer. Once the exam commences, this will continue until you have completed the exam.

Time left 0:07:19

Question 5 Not yet answered Marked out of 1 **Flag question**

- Once all the exam questions have been completed, the summary of the attempt will be displayed.

General Knowledge Quiz

Summary of attempt

Question	Status
1	Not yet answered
2	Answer saved
3	Answer saved
4	Answer saved
5	Answer saved

Return to attempt

Time left 0:06:43


This attempt must be submitted by Thursday, 14 October 2021, 10:35 AM.

Submit all and finish

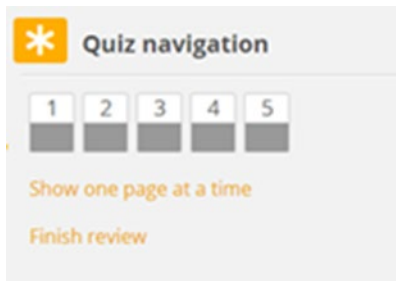Quiz navigation

1 2 3 4 5





15. You will have an opportunity to go back to any flagged questions to change / provide an answer if there is time left.
16. Click on **RETURN TO ATTEMPT** and select the question you wish to return to.
17. Once you have completed all the questions, the Quiz Navigation boxes will all have a grey section.



18. By unticking the flag, it will remove the flag from the question and the quiz navigation. To save confusion, remember to uncheck the flag once you have answered the question.
19. Once the candidate has submitted all answers, the questions and selected responses will appear. Complete the process by scrolling to the bottom of the page and click on **FINISH REVIEW**.
20. Once the candidate is satisfied that all answers have been completed, click on **SUBMIT ALL AND FINISH**.
21. The candidate will be provided a confirmation text box. Upon completion of the examination, click on **SUBMIT ALL AND FINISH**. Make sure that this green button has been clicked prior to the time expiring, to ensure that your answers are recorded, and the exam completed.
22. Candidates will only have **ONE** attempt to sit this examination.

The candidate will have a twenty (20) minute time limit on the Pre - CT examination. ASMIRT recommends that candidates use as much of that time to ensure complete familiarity with all possible combinations of the examination, as well as the “Red Flag” system, and the “Quiz Navigation” system.



CT Intermediate Level Certification Examination Summary

- 1) The candidate will be given access (via a unique username and password) to the CT Intermediate Level Certification Examination once registration processes and supervisors have been verified.
- 2) The candidate will negotiate an agreed date and time with their supervisor to sit the examination. At this agreed date and time, the examination can commence. To ensure that there is appropriate examination support from the ASMIRT certification team, Candidates sitting this examination in both Australia and countries outside of Australia will need to ensure that the examination time is conducted within an Australian time zone of 8am – 8pm.
- 3) It is the assumption of the examination markers that the “Test” Pre - CT examination has been attempted to ensure that the candidate understands both the requirements of the examination and the examination functionality.
- 4) The examination’s time duration is 180 minutes to answer 150 questions. After the allotted 180 minutes, the examination will automatically be closed.
- 5) If the candidate finishes the examination before the allotted time expires, the **SUBMIT ALL AND FINISH** button must be selected. This ensures that all answers are recorded.
- 6) This examination will be conducted over a designated period of one week. This allows for both flexibility and ease for both the candidate and supervisor. Examination marking will commence once the examination period has concluded.
- 7) All ASMIRT examinations are three hours in length. Candidates may be sitting in an examination room with other candidates sitting other examinations with the same supervisor. They may be leaving at different times depending on how quickly they complete their examination. Candidates may leave early but please be respectful of other candidates (if applicable).
- 8) Candidates are not to screen capture, take photos or write questions down during the examination.
- 9) Examination results will be emailed to candidates within a fortnight of the examination week concluding.
- 10) In the instance that there are unforeseen circumstances with the technology, the supervisor will contact the ASMIRT certification team to promptly report the problem, and a new date and time will be negotiated with the candidate to re sit the examination.

